

# Histological changes in the oviduct of rabbits after administration of cadmium

**P. Massányi<sup>1</sup>, V. Uhrín<sup>1</sup>, R. Toman<sup>1</sup>, J. Kovácik<sup>1</sup> and D. Bíro<sup>2</sup>**

*University of Agriculture,*

<sup>1</sup> *Department of Physiology and Anatomy of Farm Animals,*

<sup>2</sup> *Department of Nutrition*

*Tr. A. Hlinku 2, 949 76 Nitra, Slovak Republic*

(Received 30 April 1998; accepted 19 March 1999)

## ABSTRACT

The effects of cadmium on the oviduct of 32 rabbits were studied by light microscopy with morphometry. Cadmium was administered intraperitoneally (i.p.) to group A in a single dose of 1.5 mg/kg body weight (BW), per os (p.o.) to group B in daily doses of 1.0 mg/kg BW for a 5-month period, and also p.o., 1.0 mg/kg BW; for a 5-month period daily followed by a 7-month interval in group C. All experimental groups were compared to the control group (K), as well as to other experimental groups. Animals were examined directly after the experimental period.

The amount of epithelium in the oviduct ranged from 19.67 to 25.50%, with no significant differences. Significantly higher amounts of stroma were found in group A in comparison with group C. In the stroma, dilatation of blood vessels was evident with subsequent oedematization and diapedesis. No significant differences were found in the muscular layer.

KEY WORDS: cadmium, oviduct, histology, rabbits

## INTRODUCTION

Cadmium is chemically similar to zinc and occurs naturally with zinc and lead in sulphide ores. Some cadmium has been found in all natural materials that have been analyzed. High concentrations in air, water and soil, however, are commonly associated with industrial emission sources, particularly with non-ferrous mining and metal refining (Friberg et al., 1986).

\* Supported by the Scientific Grant Agency (VEGA), Grant No. A-66-G

Generally, it is well known that cadmium accumulates very intensively in the liver and kidneys (Renon et al., 1980; Friberg et al., 1986; Bireš et al., 1990; Massányi et al., 1995a; Nad et al., 1995; Sokol et al., 1998). Cadmium alters the growth of experimental animals (Massányi and Uhrin, 1996a), has effects on the growth of offspring (Massányi et al., 1995a), effects on the blood serum metabolic profile (Massányi et al., 1995d,e), and is responsible for changes in ovarian structure (Massányi and Uhrin, 1996b). Klaassen and Kotsonis (1977) found, in rats, a very high relationship between the concentration of cadmium in the liver and the administered dose. The highest levels were reported in the kidneys and in the liver. In our previous study (Massányi et al., 1995a), we reported that the concentration of cadmium in rabbits not treated with cadmium was 0.138 mg/kg in liver, 0.458 mg/kg in kidneys, 0.033 mg/kg in the ovaries, and 0.040 mg/kg wet tissue in the uterus. Bireš et al. (1991) have reported that the cadmium level in ewe ovaries is  $1.6 \pm 0.36$  mg/kg.

Cadmium affects reproduction. In males, cadmium produces testicular injury (Kotsonis and Klaassen, 1977). Exposure to cadmium causes vascular damage and interstitial cell oedema, leading to hemorrhage, reduced androgen production by Leydig cells, necrosis of the Sertoli cells, inhibition of spermatogenesis, and eventually testicular atrophy (Gunn et al., 1963; Toman and Massányi, 1997). Also motility of bovine spermatozoa is inhibited by cadmium chloride (Massányi et al., 1996). In females, it affects the ovaries (follicular atresia, interstitial oedema, altered hormone production) as well as the uterus (interstitial oedema, capillary modification) (Peereboom-Stegeman et al., 1987; Rehm and Waalkes, 1988; Paksy et al., 1992; Massányi and Uhrin, 1996b, 1997; Massányi et al., 1997). The histological changes and structure of the oviduct and ovary are well described (Bireš et al., 1995; Kolodzieyski and Danko, 1995; Cigánková et al., 1996; Jantošovicová et al., 1996; Danko, 1997).

The purpose of this study was to analyze oviduct structure after experimental administration of cadmium as there are no previous reports on changes in the oviduct. Our previous studies have found the highest cadmium accumulation in the oviduct in comparison with other reproductive organs (Massányi et al., 1995b,c).

## MATERIAL AND METHODS

All experiments were conducted on rabbits (Hyla, VÚZV Nitra), an animal with spontaneous ovulation, housed individually in cages. The animals (32) were divided into four groups (K, A, B, C). Eight rabbits received cadmium i.p. (1.5 mg/kg BW) in a single dose. These animals (group A) were killed 48 h after administration of cadmium ( $\text{CdCl}_2$ , Sigma, St. Louis, MO, USA). A continuous experiment (group B) was carried out on the same number (8) of animals. Cadmium was administered

daily at a dose of 1.0 mg/kg BW for 5 months in pelletized food (PD Cataj, Slovak Republic). After this period the animals were sacrificed. In group C, eight female rabbits received a cadmium dose of 1.0 mg/kg BW for 5 months daily, then administration was stopped for 7 months. To obtain histological samples, all animals in group C were killed after the experiment. Food and water were available for all animals *ad libitum*. The administered cadmium was diluted with a physiological solution to the appropriate concentration. The last group (K) was the control, and received no cadmium.

Oviducts (mid part of the ampulla) of the cadmium-treated and untreated rabbits were fixed in 10% formol (48 h), dehydrated in a graded series of ethanol and embedded in paraffin. Oviducts were sectioned by a microtome. Serial sections (5 from each animal) 10  $\mu$ m thick were stained with haematoxylin and eosin. From photographs (Docuval, Carl Zeiss Jena) based on micromorphological criteria (Weibel et al., 1966; Uhrin, 1992) the percentage of epithelium, stroma, and muscular layer were evaluated with respect to each oviduct.

The final data was subjected to basic statistical analysis (mean, SD), and to analysis of variance by Sheffe's test for each variable.

## RESULTS

In evaluating the percentage of epithelium, stroma, and muscular layer in oviducts (Table 1), we found that the highest amount of epithelium was in the group receiving cadmium continuously (25.5%). In the other groups the percentage was very similar (19.67-23.13%). No significant differences were determined.

TABLE 1

Rabbit oviduct structures in control and experimental groups, %

	Group			
	K	A	B	C
Epithelium	23.12 $\pm$ 7.30	22.11 $\pm$ 5.57	25.50 $\pm$ 6.52	19.67 $\pm$ 4.86
Stroma	19.11 $\pm$ 5.02	24.96 $\pm$ 5.33*	19.89 $\pm$ 6.09	16.79 $\pm$ 4.37*
Muscular layer	57.77 $\pm$ 11.32	52.93 $\pm$ 6.61	54.61 $\pm$ 8.80	63.55 $\pm$ 6.36

\*  $P < 0.05$  (A-C)

In comparing the stroma, we report a significantly lower amount of this parameter in the group with a 5 month daily p.o. administration with later cessation of administration in comparison with i.p. application. This result describes oedematization of the oviduct tissue, caused by disintegration of the capillary wall, after a high level of cadmium intake. Dense material on the top of well-vascularized papillary mucosa is evident after cadmium administration (Figures 1 and 2). On the

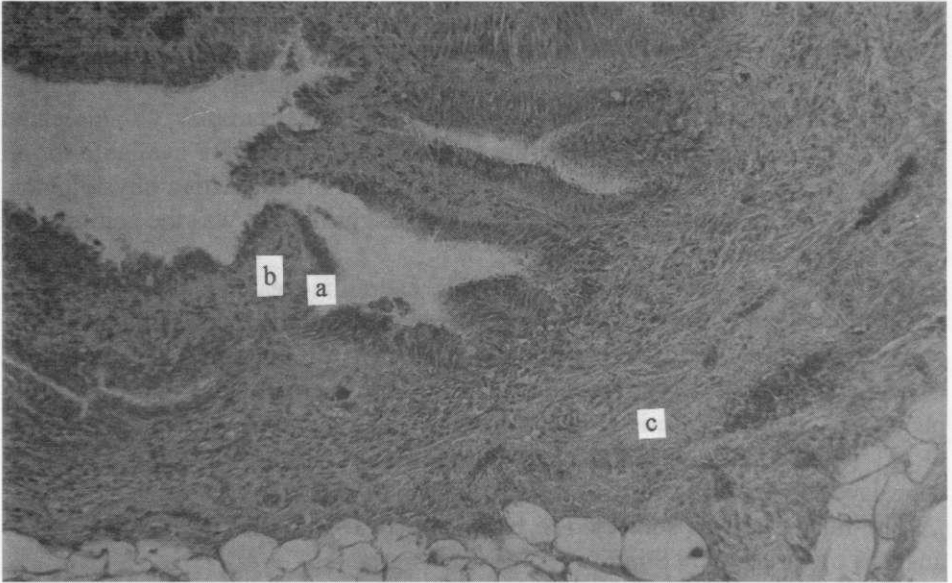


Figure 1. Histological structure of the oviduct of control. In the oviductal wall surface epithelium (a) is present, under which lays lamina propria mucosae (b) formed by connective tissue and muscular layer (c) (H-E, 200x)

other hand, we also found a relatively lower amount of stroma in group K and B compared to group A, but this decrease was not significant. The amount of muscular layer was, in all studied groups, in the range of 52.94 to 63.55% with no significant difference.

## DISCUSSION

The biological effects of cadmium deserve attention for many reasons. Its use in different industrial processes and products has increased its presence in the environment.

Cadmium exposure in our experiment resulted in changes in oviduct structure, mainly the stroma and epithelium, with changes in the capillary wall structure. A similar result was found in the endometrium of the uterus where the percentage of stroma was significantly higher after i.p. administration of cadmium (Massányi and Uhrin, 1997). Oedematization of the uterus with disintegration in the blood vessels and subsequent diapedesis were evident.

There are no previous reports about structural changes in the oviduct after administration of cadmium. It is believed that cadmium bound to carrier proteins is able to enter the oviduct lumen only in small quantities (Paksy et al., 1992). Moreover, due to its poor blood supply, the oviduct contains relatively lower levels of

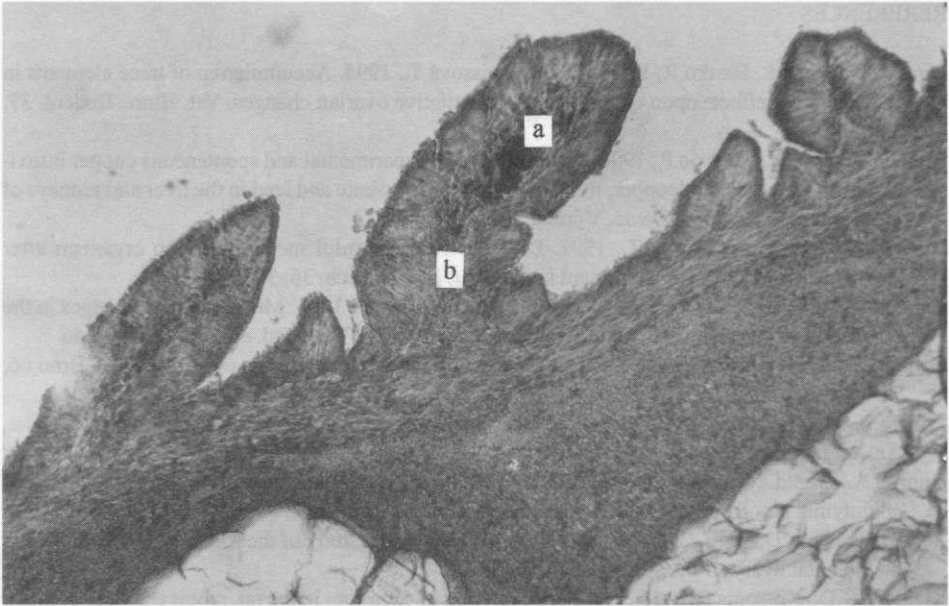


Figure 2. After i.p. administration of cadmium dense granules (a) are present in lamina propria mucosae (b) (H-E, 200x)

cadmium compared to the corpora lutea in pseudopregnant rats treated with cadmium at a dose of 3.5 mg/kg (Paksy et al., 1990). Possible indirect influence of cadmium on oviduct function is perhaps caused by a dose-dependent drop in ovarian secretion of progesterone (Paksy et al., 1992).

Changes in oviduct structure are caused by changes in the blood vessel wall, and subsequent diapedesis. Similar alterations are reported in the uterus (Massányi and Uhrin, 1997). Peereboom-Stegeman et al. (1987) have studied the small vessels in the myometric layer of the uteri in rats exposed subcutaneously to the cadmium. The thickness of the media was analyzed and an inventory was made of the morphology of the media, the endothelial layer, and the perivascular connective tissue. A dose- and time-related increase of the thickness of the media was demonstrated. At the higher dose, signs of a perivascular inflammatory reaction were observed. From these, as well as from our data it is evident that cadmium causes disorders in the blood vessels wall with significant oedematization.

#### ACKNOWLEDGMENTS

We would like to express our gratitude to Mrs. P. Sýkorová and M. Beneová for technical assistance.

## REFERENCES

- Bíreš J., Maracek I., Bartko P., Bírešová M., Weissová T., 1995. Accumulation of trace elements in sheep and the effects upon qualitative and quantitative ovarian changes. *Vet. Hum. Toxicol.* 37, 349-356
- Bíreš J., Vrzgula L., Mudroo P., 1990. The influence of experimental and spontaneous copper intoxication on the content of copper, iron, zinc, cadmium, arsenic and lead in the liver and kidneys of ewes and their foetuses. *Živoc. Výroba* 35, 159-168
- Bíreš J., Vrzgula L., Juhássová Z., 1991. Distribution of harmful metals in sheep organism after experimental industrial contaminant intake. *Vet. Med.-Czech.* 36, 361-371
- Cigánková V., Krajnieáková M., Kokardová M., Tomajková E., 1996. Morphological changes in the ewe uterine tube (oviduct) epithelium during puerperium. *Vet. Med.-Czech.* 41, 339-346
- Danko J., 1997. Ovarian mass, size and number of follicles in postparturient ewes. *Acta Vet. Brno* 66, 71-74
- Friberg L., Nordberg G.F., Vouk V. (Editors), 1985. *Handbook on the Toxicology of Metals*. Elsevier, Amsterdam, pp. 130-184
- Gunn S.A., Gould T.C., Anderson W.A.D., 1963. The selective injurious response of testicular and epididymal blood vessels to cadmium and its prevention by zinc. *Amer. J. Pathol.* 42, 685-702
- Jantošovicová J., Danko J., Jantošovic J., 1996. A histological study of the follicular development in the prenatal ovary of the sheep. *Folia Vet.* 40, 15-20
- Klaassen C.D., Kotsonis F.N., 1977. Biliary excretion of cadmium in the rat, rabbit and dog. *Toxicol. Appl. Pharmacol.* 41, 101-112
- Kolodzieyski L., Danko J., 1995. A histological, histochemical, and immunohistochemical picture of the ovary of a hermaphrodite goat. *Folia Vet.* 39, 107-110
- Kotsonis F.N., Klaassen C.D., 1977. Toxicity and distribution of cadmium administered to rats at sublethal doses. *Toxicol. Appl. Pharmacol.* 41, 667-680
- Massányi P., Lukács N., Trandžik J., 1996. In vitro inhibition of the motility of bovine spermatozoa by cadmium chloride. *J. Environ. Sci. Health A31*, 1865-1879
- Massányi P., Najmik F., Renon P., 1995c. Cadmium concentration in reproductive organs of cattle (in Italian). *Arch. Vet. Ital.* 46, 62-66
- Massányi P., Toman R., Valent M., Eupka P., 1995e. Evaluation of selected parameters of a metabolic profile and levels of cadmium in reproductive organs of rabbits after an experimental administration. *Acta Physiol. Hung.* 83, 267-273
- Massányi P., Toman R., Valent M., Jones Q., 1995d. Serum mineral profile of rabbits after an experimental administration of cadmium. *J. Environ. Sci. Health A30*, 2221-2227
- Massányi P., Toman R., Najmik F., 1995b. Concentrations of cadmium in ovary, oviductus, uterus, testis and tunica albuginea of testis in cattle. *J. Environ. Sci. Health A30*, 1685-1692
- Massányi P., Uhrín V., 1996a. Growth of rabbits after a peroral administration of cadmium and its distribution. *Acta Zootech.* 51, 89-93
- Massányi P., Uhrín V., 1996b. Histological changes in the ovaries of rabbits after an administration of cadmium. *Reprod. Dom. Anim.* 31, 629-632
- Massányi P., Uhrín V., 1997. Histological changes in the uterus of rabbits after an administration of cadmium. *J. Environ. Sci. Health A32*, 1459-1466
- Massányi P., Uhrín V., Toman R., 1995a. Distribution of cadmium and its influence on the growth of offspring after an experimental application to female rabbits. *J. Environ. Sci. Health A30*, 51-62
- Massányi P., Uhrín V., Valent M., 1997. Correlation relationship between cadmium accumulation and histological structures of ovary and uterus in rabbits. *J. Environ. Sci. Health A32*, 1621-1635

- Nai P., Birešová M., Legát J., 1995. The effects of feeding emissions from a metal-producing plant upon the immune system. *Vet. Med.-Czech.* 40, 101-104
- Paksy K., Náray M., Varga B., Olajos F., Folly G., 1992. Altered ovarian progesterone secretion induced by cadmium fails to interfere with embryo transport in the oviduct of the rat. *Reprod. Toxicol.* 6, 77-83
- Paksy K., Varga B., Folly G., 1990. Long-term effects of a single cadmium chloride injection on the ovulation, ovarian progesterone and estradiol-17- $\beta$  secretion in rats. *Acta Physiol. Hung.* 76, 245-252
- Peereboom-Stegeman J.H.J.C., Jongstra-Spaapen E., Leene W., Oosting H., Venema H., De Moor E., Gerrissen W.J., 1987. The effects of long-term exposure to cadmium on the small blood vessels in the rat uterus : A light microscopic study. *Ecotoxicol. Environ. Safety* 14, 288-297
- Rehm S., Waalkes M.P., 1988. Cadmium-induced ovarian toxicity in hamsters, mice, and rats. *Fund. Appl. Toxicol.* 10, 635-647
- Renon P., Soncini G., Cantoni C., 1980. Cadmium in organs and meat of horses (in Italian). *Arch. Vet. Ital.* 31, 5-7
- Sokol J., Uhrin V., Massányi P., Breyl I., Košutzký J., Uhrin P. (Editors), 1998. Cadmium and its Occurrence in the Animal Organism. State Veterinary Service of Slovak Republic. Bratislava, pp.116
- Toman R., Massányi P. (Editors), 1997. Structural Changes of Testis and Epididymis of Rabbit after an Administration of Cadmium. University of Agriculture Nitra Press. Nitra (Slovak Republic), pp. 83
- Uhrin V. (Editor), 1992. Functional Morphology of Cow Oviduct and Uterine Epithelium. RIAP, Slovak Academic Press. Bratislava, pp.169
- Weibel E.R., Kistler G.S., Scherle W.F., 1966. Practical stereological methods for morphometric cytology. *J. Cell Biol.* 30, 23-38

## STRESZCZENIE

### Zmiany histologiczne w jajowodzie królików po podaniu kadmu

Doświadczenie przeprowadzono na 32 królikach, przy zastosowaniu mikroskopu z morfometrem. Kadm (Cd) podawano zwierzętom grupy A dootrzewnowo (i.p.) w jednorazowych dawkach w ilości 1,5 mg/kg masy ciała (m.c.); grupy B – doustnie (p.o.) przez 5 miesięcy, w dziennych dawkach po 1 mg/kg m.c. oraz grupy C doustnie, po 1 mg/kg m.c. przez 5 miesięcy, po czym przez następne 7 miesięcy nie podawano Cd. Grupę kontrolną (K) stanowiły zwierzęta, które nie otrzymywały Cd.

Nie stwierdzono różnic między grupami w ilości nabłonka w jajowodzie, a otrzymane wartości wahały się od 19,6 do 25,9%, podobnie jak ilość warstwy mięśniowej (52,9 do 63,5%). W grupie A w porównaniu z grupą C istotnie większy ( $P < 0,01$ ) był udział zrębu (25,0 vs 16,8%). W zrębie wyraźne było poszerzenie naczyń krwionośnych, a następnie obrzęknięcie i diapedeza.